

## First record of dicephalism in the four-lined snake *Elaphe quatuorlineata* Lacépède, 1789 (Serpentes: Colubridae) from Montenegro

### Prva najdba dvoglavega primerka progastega goža (*Elaphe quatorlineata*) v Črni Gori

Sladana GVOZDENOVIC, Montenegrin Ecologist Society, Bulevar Sv. Petra Cetinjskog 73, Podgorica, Montenegro;  
E-mail: sladjana87gvozdenuvic@yahoo.com  
Nikola ČAVOR, Trg Dara Petkovića, Tivat, Montenegro

Dicephalism, also known as polycephaly or dicephaly, is a phenomenon of an animal having two heads (Kompanje & Hermans 2008). The existence of two-headed animals is well documented in mammals and reptiles (Hoser & Harris 1995, Swanson et al. 1997, Diong et al. 2003, McAllister & Wallach 2006, Wallach 2007, Spadola & Insacco 2009, De Albuquerque et al. 2010, Pezdirc et al. 2013). The first known appearance of dicephalism in reptiles is the 120 million-year-old fossil found in China (Buffetaut et al. 2007). In a review of 950 cases of dicephalism in snakes, it has been shown that two-headed individuals occur in 169 species of 93 genera in 8 families (Wallach 2007). There are 116 reports on two-headed snakes from Europe (Wallach 2007).

Two-headed snakes are rare in nature, but can occur more frequently in captivity (Wallach 2007). There are many possible causes of dicephaly: incomplete division of a single embryo; partial fusion of two embryos; abnormally low or high temperatures during incubation or gestation; regeneration after an embryonic lesion; anoxia during embryonic development; toxic effects of metabolic secretions during a prolonged sojourn in the oviduct; inbreeding depression from small population gene pools, back-crossing, designer morphs, and albinos; hybridization; environmental pollution; chemical toxins in captivity or exposure to radiation (Wallach 2007).

On 29.10.2014, during our fieldwork study on reptiles and amphibians of the Montenegrin coast, we found a live two-headed four-lined snake (*Elaphe quatuorlineata* Lacépède, 1789) juvenile (Fig. 1). The snake was found on the car parking lot at Dobrota, Kotor (42° 26' 32.40" N, 18° 46' 12.80" E; 5 m a.s.l.) (Fig. 2), where a cat was playing with it. Heads were completely separated, well developed and both with two eyes. It was about 20 cm long, but we could not determine the gender. After taking the photo and coordinates we left the snake where we found it.

Wallach (2007) reports on two-headed *Elaphe quatuorlineata* individuals from Europe, but without exact location or country. Our observation represents a novel contribution to the knowledge on dicephalism in natural populations of snakes, and is the first reported record of *Elaphe quatuorlineata* dicephaly in Montenegro.

### References


- Buffetaut E., Jianjun L., Haiyan T., He Z. (2007): A two-headed reptile from the Cretaceous of China. *Biol. Lett.* 3: 80-81.
- Diong C.H., Tan L.K.A., Leh C.M.U. (2003): Axial bifurcation in a bicephalic *Chelonia mydas* embryo. *Chel. Cons. Biol.* 4: 725-727.
- De Albuquerque N.R., Arruda W.S., Costa A.S., Galharte R.C.V., Vargas L.G.H., Moreno I.H. (2010): A dicephalic yellow anaconda snake, *Eunectes notaeus* (Serpentes: Boidae), from Southern Pantanal, Brazil. *J. Nat. His.* 44: 1989-1994.
- Hoser R., Harris P. (1995): A second case of bicephalism in queensland carpet snakes (*Morelia spilota mcdowelli*) (Serpentes: Phyttonidae). *Herpetofauna* 3: 61.
- Kompanje E.J.O., Hermans J.J. (2008): Cephalopagus conjoined twins in a Leopard cat (*Prionailurus bengalensis*). *J. Wildl. Dis.* 44(1): 177-180.
- McAllister C.T., Wallach V. (2006): Discovery of a dicephalic Western diamondback Rattlesnake, *Crotalus atrox* (Serpentes: Viperidae), from Texas, with a summary of dicephalism among members of the genus *Crotalus*. *J. Arkansas Acad. Sci.* 60: 67-73.

Pezdirc M., Žagar A., Carretero M.A. (2013): First record of dicephalism in *Vipera ammodytes* (Linnaeus, 1758), from Slovenia. *Herpetozoa* 26(1/2): 94-95.

Swanson S., Van Breukelen F., Kreiser B., Chiszar D., Smith H.M. (1997): A double-bodied midland water snake and additions to literature on ophidian axial bifurcation. *Bull. Chi. Herp. Soc.* 32: 80-83.

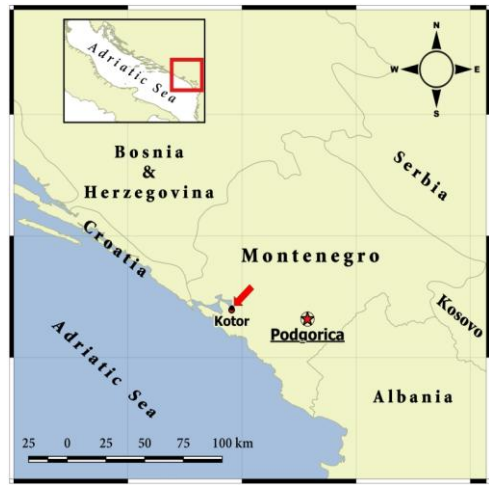Spadola F., Insacco G. (2009): Newborn dicephalic *Podarcis sicula*. *Acta Herp.* 4: 99-101.

Wallach V. (2007): Axial bifurcation and duplication in snakes. Part I. A synopsis of authentic and anecdotal cases. *Bull. Maryland Herp. Soc.* 43: 57-95.



**Figure 1.** *Elaphe quatuorlineata* with two heads found on 29.10.2014 at Dobrota, Kotor (photo: N. Čavor).

**Slika 1.** *Elaphe quatuorlineata* z dvema glavama, najden 29.10.2014 v Dobroti, Kotor (foto: N. Čavor).



**Figure 2.** Map with marked locality (red circle) where the two-headed *Elaphe quatuorlineata* was found.

**Slika 2.** Karta z označeno lokaliteto (rdeč krog), kjer je bil najden dvooglavi *Elaphe quatuorlinea*.